

How to Cite:

Manyam, A., Pichika, K., Kumar, J. S., Devi, G., Publishing, L., Narayan, A., & Natarajan, V. (2022). Disseminated Nocardia infection in a patient with systemic lupus erythematosus: A case report. *International Journal of Health Sciences*, 6(S3), 7963–7972. <https://doi.org/10.53730/ijhs.v6nS3.7889>

Disseminated Nocardia infection in a patient with systemic lupus erythematosus: A case report

Anandamuni Manyam*

Post graduate resident (Medicine), Department of Medicine, SRM Medical College & Research Centre

Karthik Pichika

Professor (Medicine), Department of Medicine, SRM Medical College & Research Centre

J. S. Kumar

Senior resident (Medicine), Department of Medicine, SRM Medical College & Research Centre

Geetha Devi

Professor (Medicine), Department of Medicine, SRM Medical College & Research Centre

Lakshmanan

Professor (Medicine), Department of Medicine, SRM Medical College & Research Centre

Ashwin Narayan

Professor (Medicine), Department of Medicine, SRM Medical College & Research Centre

Vishal Natarajan

Post graduate resident (Medicine), Intern, Department of Medicine, SRM Medical College & Research Centre

Abstract---28 year old female who was under treatment for systemic lupus erythematosus with oral prednisolone for 4 months presented with history of fever with chills, productive sputum, pleuritic chest pain, exertional breathlessness, anorexia and was found to have signs of pneumonia clinically on the right side. She also gave history of gradual painful diminution of vision in her left eye and two episodes of generalized tonic clonic seizures just prior to admission. Despite empirical treatment with antibiotics, her condition gradually

deteriorated. A computer tomography – thorax (HRCT), showed linear and nodular opacities in right middle lobe segments and right medial basal segment along with homogenous opacity with multiple cavitations noted in the lower lobe of right lung with air bronchogram. MRI- brain showed multiple conglomerate foci of ring enhancing lesions with moderate surrounding edema seen in bilateral cerebral hemispheres, irregular thickening of choroid seen in left eye with hyperintense vitreous cavity showing blooming. CSF did not show any abnormality. *Nocardia farcinica* was isolated from the vitreous. Diagnosis of Disseminated nocardiosis involving lungs, brain and left eye was made. The patient was treated with intravenous cefoperazone sulbactam, intravenous amikacin and oral trimethoprim/sulfamethoxazole with a good clinical response, and there has been no recurrence of the infection. She is on regular follow up.

Keywords---*Nocardia*, disseminative, Systemic lupus erythematosus, vitreous humor, trimethoprim-sulphmethoxazole.

Introduction

Nocardia spp. are gram-positive aerobic bacteria, which are commonly found in soil, water and air¹. Nine species have been associated with human disease (*N. asteroides*, *N. brasiliensis*, *N. otitidiscaviarum*, *N. farcinica*, *N. abscessus*, *N. nova*, *N. transvalensis*, *N. pseudobrasiliensis* and *N. africana*)². Nocardiosis is a vital, but often ignored, infectious disease in immunocompromised hosts, which is particularly serious in the absence of timely diagnosis and therapy. It has a worldwide incidence, does not exhibit ethnic predominance, seems to be more frequent in patients aged 30–40 years³, and is two to three times more common in males than in females⁴. Nocardiosis is a systemic disease commonly occurring as an acute, subacute or chronic infectious disease in cutaneous, pulmonary and disseminated forms. Nocardiosis can occur in association with a deficiency in cellular immunity⁵– such as human immunodeficiency virus (HIV) infection, other immunodeficiency syndromes, or chronic use of systemic steroids – or in immunocompetent hosts.

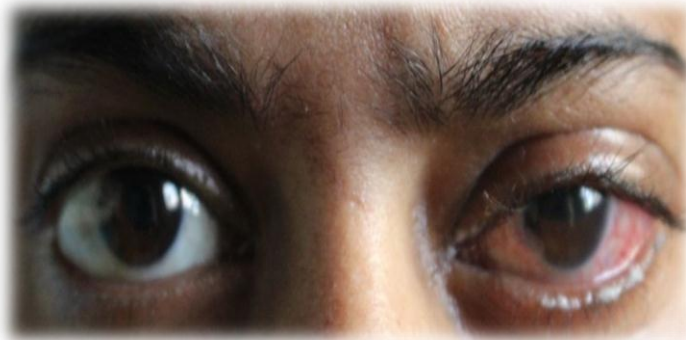In the immunocompromised patient the infection starts in the lung, before spreading to the central nervous system (CNS) or other organs. Disseminated nocardiosis to the brain, kidneys, joints or eyes can occur by haematogenous spread. In contrast, in the immunocompetent patient the disease typically takes a chronic course in a single organ or region⁶. They are branching, beaded filamentous Gram (+), weakly acid fast bacteria causing suppurative necrosis and frequent abscess formation⁽⁷⁾. Route of entry may be inoculation due to trauma (in cutaneous, lymphocutaneous and subacute form), inhalational exposure in pulmonary and brain disease and wounds after surgery⁽⁸⁾. Conditions associated with increased risk are pulmonary alveolar proteinosis, cirrhosis, renal failure, SLE, systemic vasculitis, ulcerative colitis, sarcoidosis, Whipple's disease, hypogammaglobinemia, Cushing's syndrome, lymphoreticular malignancies, bone marrow/stem cell/organ transplant patients, HIV with CD4 <50 and

immunocompromised people on corticosteroid therapy(9). . We describe a case of systemic infection (manifesting as pulmonary, ocular and brain abscesses) caused by *Nocardia farcinica* in a patient with systemic lupus erythematosus (SLE) on long-term oral corticosteroid therapy.

Case report

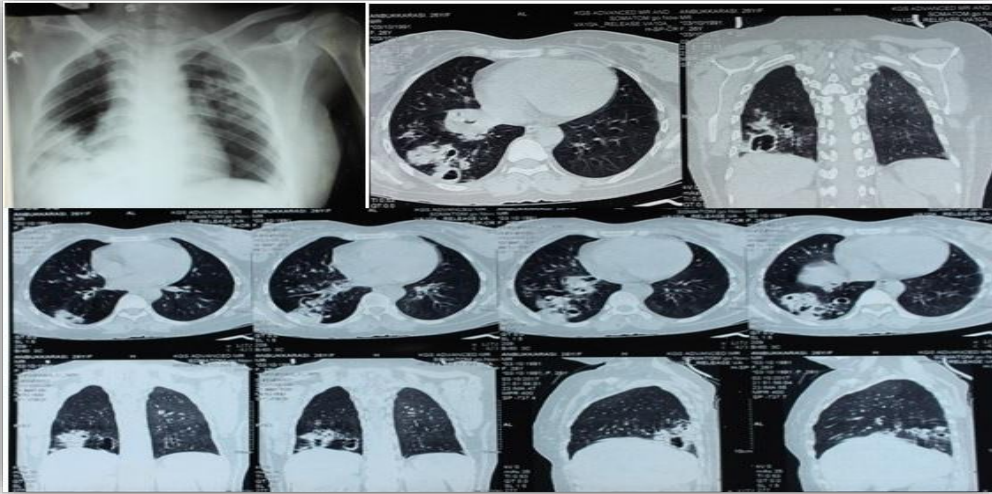
A 28-year female, presented with 5 day history of fever, low grade associated with chills and rigors, productive cough with yellowish sputum. Patient also had history of breathlessness for last 20 days associated with right sided chest pain on inspiration. Patient had two episodes of generalized tonic clonic convulsions. She had past history of Deep venous thrombosis of lower limbs in the first pregnancy diagnosed in the eight month of gestation and was treated accordingly. She was also diagnosed to have Systemic lupus erythematosus with secondary Anti phospholipids antibody syndrome after relevant investigations and was put on azathioprine and corticosteroids.

On examination, she was febrile and coarse crepitations were audible over the infrascapular area on the right side with decreased air entry on the lower lobe of right lung. During the course in the hospital, patient developed left eye diminished vision associated with pain and redness. Ophthalmic examination showed visual acuity of counting fingers at 2 feet in the left eye. Her pupils were reacting to light. Introcular pressure was normal. The conjunctiva showed fine papillary reaction. Patchy infiltrations were predominantly seen in anterior stromal and findings were consistent with endophthalmitis. On further examination, choroidal mass was noted in left eye with diffuse iridocyclitis.

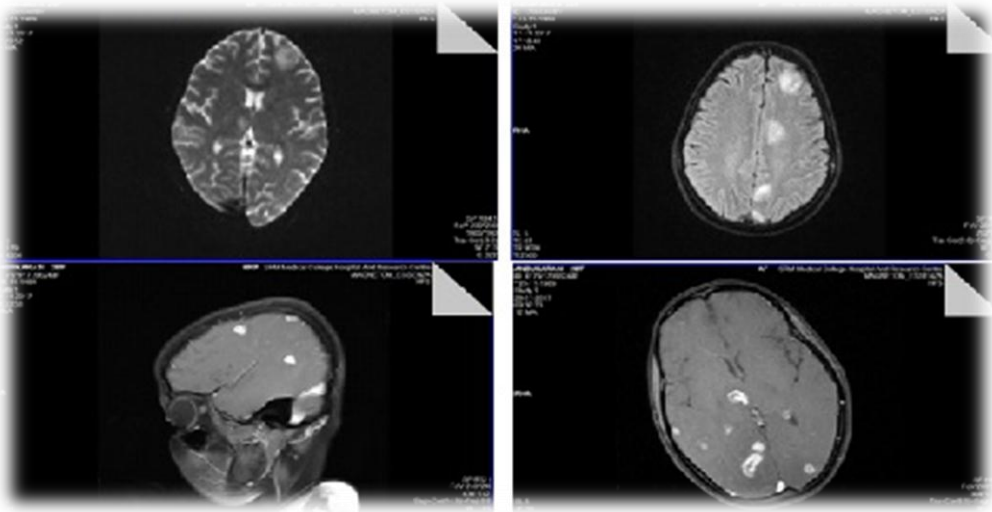


Laboratory finding included a haemoglobin level of 5.9g/dl, a leucocyte count of 14,800/cu mm (94% polymorphonuclear cells, 5% lymphocytes) an ESR of 55mm in the first hour, total protein level of 6.1g/dl an albumin level of 2.9d/dl, a gamma globulin level of 3.2g/dl. Peripheral smear showed severe normocytic normochromic anaemia with neutrophilic predominance. Chest radiography revealed right lower lobe consolidation with cavities and bronchiectasis. A computer tomography (HRCT), showed linear and nodular opacities in the left upper lobe lingular, apical and posterior segments of right upper lobe, right middle lobe segments and right medial basal segment along with homogenous

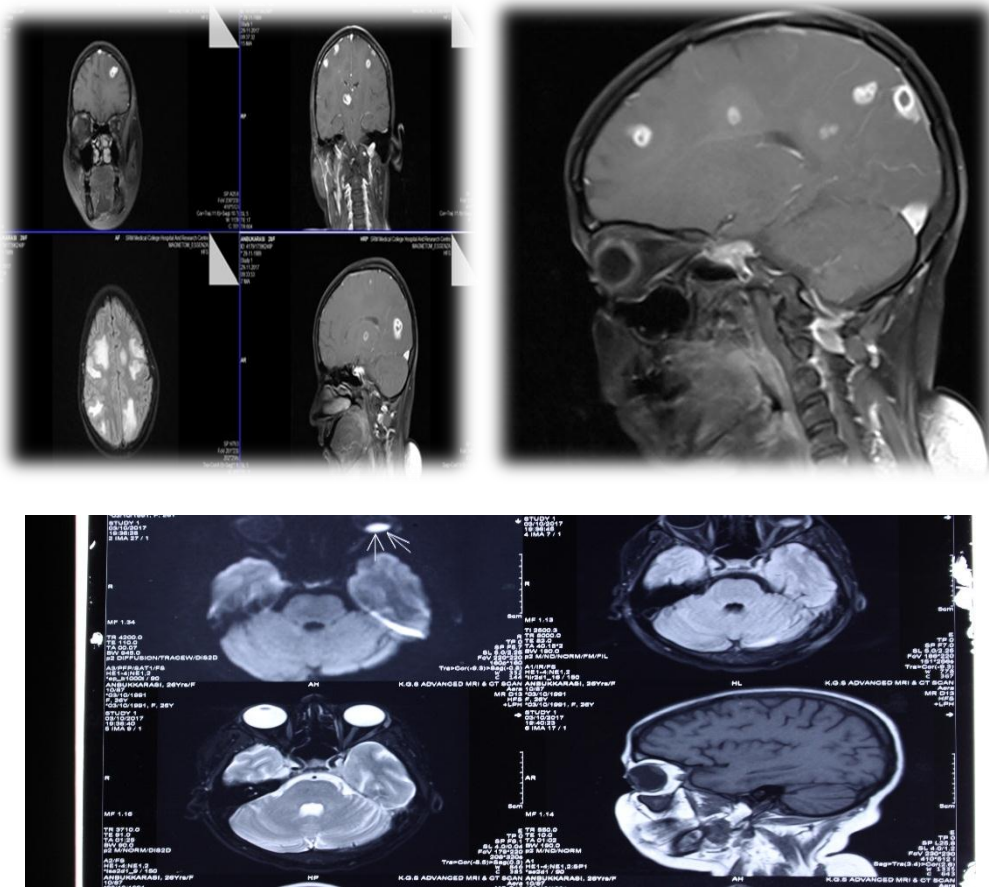
opacity with multiple cavitations noted in the lower lobe of right lung with air bronchogram and cystic bronchiectatic changes.



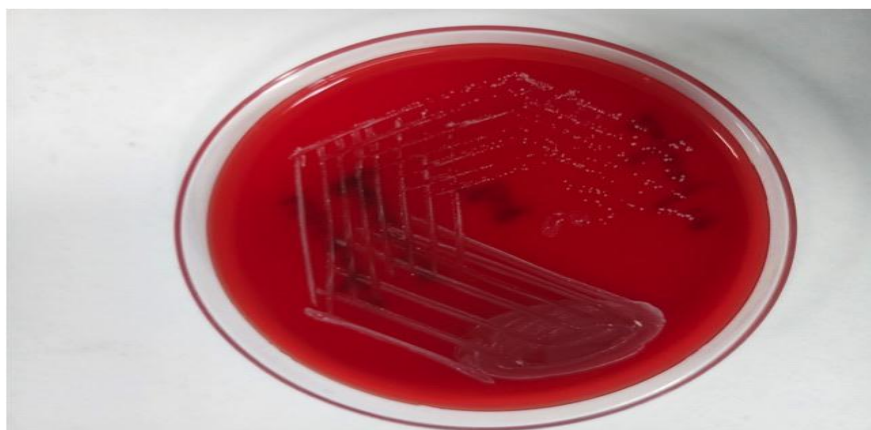MRI Brain with MRA showed multiple T2/FLAIR ill defined hyperintense lesions with few of the lesions showing diffusion restriction and small hypointense areas within seen in both cerebral hemispheres. CSF did not show any abnormality.



MRI- brain with contrast showed multiple conglomerate foci of ring enhancing with lesions with moderate surrounding oedema seen in bilateral cerebral hemispheres, irregular thickening of choroid seen in left eye with hyperintense vitreous cavity showing blooming on GRE.



MRspectroscopy showed presence of lipid and lactate peak, mild reduction of NAA peaks suggestive of Nocardiosis. Bronchial wash for gram staining, KOH mount, AFB smears, cytology and galactomannan did not yield much information. Sputum culture showed moderate growth of klebsiella pneumonia and candida albicans. Vitrectomy was done for the choroidal mass in left eye. The subretinal fluid was sent of culture and sensitivity. The subretinal fluid culture also showed a gram-positive acid fast bacterium. The isolates were presumptively identified as *Nocardia Farcinica*.



Based on culture and sensitivity reports, Patient was treated with antibiotics cefoperazone/sulbactam and amikacin along with sulfomethoxazole and trimethoprim. During first week of treatment, patient's general condition improved. Clinical and radiological improvement of brain and lungs were evident within a couple of weeks. Patient was discharged on oral sulfomethoxazole and trimethoprim and is on regular follow up.

Discussion

Disseminated nocardiosis is defined as lesions containing nocardia found at more than one body location [10]. Nocardia is an opportunistic pathogen and most of all nocardia infections occur in persons with some degree of immunosuppression. In humans, nocardial infection can present in a variety of forms, ranging from localized cutaneous disease to disseminated, multi-organ invasion. Cutaneous or lymphocutaneous disease is typically seen in immunocompetent individuals. Pulmonary nocardiosis typically occurs after inhalation of environmental organisms. The lungs are the most frequent primary site of systemic nocardiosis (60-80% of cases) with a variety of clinical presentations including cough, dyspnoea, fever, night sweats, weight loss and pleuritic chest pain. The central nervous system has been shown to be involved in 20-44% of patients with disseminated Nocardiosis. Nocardia infection may present with ocular involvement, but at least one other site is invariably affected, (11) often lung or brain. The brain is a particular site of dissemination, which may be explained in part by the organism's molecular preference to invade brain tissue. Brain abscesses caused by *N. farcinica* are associated with a high mortality rate of up to 20% in immunocompetent patients and 55% in immunocompromised patients (12). Disseminated nocardia tend to behave as pyogenic bacteria and the result is typically a suppurative abscess at the embolic end point. The abscess tends to progress or enlarge into the surrounding tissue by filamentous extension and self-limitation of the disease is rare [7] When patients present with concomitant brain and lung lesions, the differential diagnoses to be kept in mind include tuberculosis, neoplastic disease, and Nocardiosis. Mok CC et al reported a similar case of disseminated nocardiosis with involvement of lungs and eye in a patient with systemic lupus erythematosus (8).

Diagnosis is often a problem and hence it is important to have a high index of suspicion in the appropriate clinical settings, especially in patients not responding to antituberculous treatment. Imaging findings are not specific for nocardiosis. In the chest, it can present as pulmonary consolidation, irregular nodular parenchymal densities, solitary irregular lung mass, interstitial reticular pattern, pleural effusion, or lymphadenopathy, but none of these is a specific diagnostic feature.[7] Typical radiological features in a cerebral abscess include a hyperintense lesion on diffuse weighted imaging and ring enhancing lesions encircling a central necrotic focus. Occasionally multiple concentric rings are seen that vary with intensity (13). Intraocular infection is a feature of the immunodeficient patient and this may present acutely with endophthalmitis, or sub-acutely with a sub-retinal focus. The differential diagnosis of sub-retinal abscess includes infection by *Klebsiella* spp.,³ *Pseudomonas* spp.,⁵ *M. tuberculosis*, *Staph. Aureus* and *Strep. viridans*. (14) *Nocardia* should be part of this differential diagnosis. Involvement of eyes in immunocompromised individuals has been documented in other studies as well. Usually imaging is non-specific, pleomorphic and not pathognomonic (15). For this reason microbiological examination, with appropriate evaluation of the sample for smear and culture, became the main method to ascertain the diagnosis of *Nocardia* infection (16).

Nocardia spp. infection can be observed and confirmed by subculture and positive microscopic detection of a branching gram-positive rod and modified acid-fast stain. Demonstration of marked polymorphonuclear leukocytes in the pus, in the absence of regional lymph node enlargement, is said to be characteristic. [17] . An aggressive diagnostic strategy that includes BAL and tissue biopsies may significantly improve the outcome. Isolation of *Nocardia* in any patient, from anybody source, should always be regarded as significant (16). In this patient, The subretinal fluid culture showed a gram positive acid fast bacterium was isolated. The isolates were presumptively identified as *NOCARDIA FARIGINIA*. *N. fariginica* is being increasingly recognized as an agent of disseminated human Nocardiosis particularly in immunocompromised hosts. The correct and timely diagnosis of *Nocardia* infection and the institution of proper therapy can be life saving (18), but a delay is not uncommon. The exact identification of the species is important, since different species have different susceptibility profiles. While waiting for the results, empirical treatment must start. For the last 60 years sulfonamides have been the therapy of choice for this disease (19).

Trimethoprim/sulfamethoxazole (cotrimoxazole) has been the drug most often employed, owing to its pharmacokinetics and to particularly good CNS penetration. In patients with disseminated infection, however, monotherapy is not recommended (19) and the combination drugs viz imipenem, amikacin, ampicillin, third-generation cephalosporins, fluoroquinolones, or minocyclines; appears to be superior to other antibiotics (20) The usually recommended duration of therapy is for 6-12 months.[21]. Once appropriate parenteral therapy is initiated, infected individuals typically show a clinical response within the first 5 to 7 days. Usually, 3 to 6 weeks of intravenous therapy is required before switching the patient to appropriate oral antibiotics [23]. If possible, immunosuppressive drugs are occasionally tapered or removed to promote clearance of the organisms. More invasive disease often requires 12

months or longer of antimicrobial therapy [23]. Immunocompromised patients, particularly those with severe disease and high levels of immunosuppression, may end up on long-term therapy or prophylaxis for life, at the discretion of the treating clinician. The decision to intervene surgically varies from case to case.

Mamelak *et al.* (1994) (21) recommended the use of aspiration or craniotomy and excision for brain abscesses larger than 2.5 cm, and abscesses that fail to shrink after 4 weeks of antibiotic therapy. Even though long-term antibiotics are being continued to ensure disease control, 13% of nocardial endophthalmitis patients were not effectively treated using this trimethoprim/sulfamethoxazole alone [24]. For this reason, intravitreal amikacin has been reported as an alternative treatment strategy and can be used in combination with systemic antimicrobials to achieve control of the nocardial infection. The systemic and visual prognosis for patients with *Nocardia* endogenous endophthalmitis is extremely guarded to poor in many cases because of secondary complications, such as retinal detachment, that may lead to visual loss. Brown-Elliott *et al* (25) previously reported that relapse was rare in cases treated for 4–6 months, although prolonged antibiotic chemotherapy may be required for complete eradication. Furthermore, it has been reported that systemic symptoms disappear after ≥ 6 weeks, and that immunosuppressed patients should be treated for ≥ 6 months and patients with central nervous system involvement should sustain treatment for 12 months (9).

Regarding our patients, corticosteroid was tapered and stopped. *In vitro* susceptibility tests were done and intravenous antibiotics, cefoperazone sulbactam and amikacin were administered for four weeks along with oral Trimethoprim/sulfamethoxazole administered. Vitrectomy was done for the choroidal mass in left eye. Clinical and radiological improvement of brain and lungs were evident within a couple of weeks. Despite adequate antibiotic therapy, vision in the left eye could not be restored. The patient is on regular follow up with oral Trimethoprim/sulfamethoxazole, immunosuppressive agents for systemic lupus erythematosus. The mortality rate in immunosuppressed patients with pulmonary and/or disseminated *Nocardia* infection is as high as 65% [22]. Early identification of infection is very important, especially because the infection can entirely mimic the presentation of a flare-up of underlying disorders, and mortality is usually caused by a delay in diagnosis and treatment. Greater awareness of this disease entity may help to reduce its incidence and further improve its outcome in systemic lupus erythematosus patients.

Conclusion

Patients with SLE are at high risk for opportunistic infections because of cellular immunosuppression caused by lupus itself or by its treatment. we report a case of disseminated infection due to *N. farcinica* in an SLE patient receiving long-term steroid therapy, which was successfully treated with antibiotic therapy. Nocardiosis can be a difficult infection to identify and treat. Clinical and microbiological manifestations of nocardiosis vary for different *Nocardia* spp.; therefore accurate identification of the species is crucial for effective diagnosis and treatment. Invasive sampling procedures are often needed to prove infection. *N. farcinica* presents the unique treatment challenge of being resistant to many of the common drugs used to treat other *Nocardia* species. Nocardiosis should be

suspected in immunosuppressed patients who present with abscesses in multiple organs and appropriate therapy should be recommended.

Consent

Written informed consent was obtained from the patient for publication of this report and any accompanying images.

References

- Faghri J, Bourbour S, Moghim S, Meidani M, Safaei HG, Hosseini N, Esfahani BN, Fazeli H, Sedighi M. Comparison of three phenotypic and deoxyribonucleic acid extraction methods for isolation and identification of *Nocardia* spp. *Adv Biomed Res.* 2014;3:151–154. doi: 10.4103/2277-9175.137839.
- Zaatreh M, Alabulkarim W. Images in clinical medicine. Disseminated central nervous system nocardiosis. *N Eng J Med* 2006; 354: 2802. PMID: 16807417
- McNeil M.M., Brown J.M. 1994; The medically important aerobic actinomycetes: epidemiology and microbiology. *Clin Microbiol Rev.* 7 :357. PubMed PMID: 17651365
- Yildiz O., Doganay M. 2006; Actinomycoses and *Nocardia* pulmonary infections. *Curr Opin Pulm Med.* 12 :228. doi:http://dx.doi.org/10.1097/01.mcp.0000219273.57933.48
- Hamadani M., Benson D.M. Jr, Blum W., Garzon R., Devine S.M. 2008; Pulmonary *Nocardia Aspergillus* co-infection in a patient with chronic graft-versus-host disease. *Transpl Infect Dis.* 10 :24. doi: http://dx.doi.org/10.1111/j.1399-3062.2007.00268.x. PubMed PMID: 2285288.
- Ambrosioni J., Lew D., Garbino J. 2010; Nocardiosis: updated clinical review and experience at a tertiary center. *Infection.* 38 :89. doi:http://dx.doi.org/10.1007/s15010-009-9193-9. PubMed PMID: 20306281.
- Beaman, B.L. and Beaman, L. *Nocardia* species (host-parasite relationships) . *Clin Microbiol Rev.* 1994; 7: 213–264
- Mok CC, Yuen KY, Lau CS. Nocardiosis in systemic lupus erythematosus. *Semin Arthritis Rheum.* 1997;26(4):675–683. doi: 10.1016/S0049-0172(97)80003-0.
- Korkmaz, C., Aydinli, A., Erol, N. et al. Widespread nocardiosis in two patients with Behcet's disease. *Clin Exp Rheumatol.* 2001; 19: 459–462
- Wakhlu A, Agarwal V, Dabadghao S, Prasad KN, Nityanand S. Nocardiosis in patients of chronic idiopathic thrombocytopenic purpura on steroids. *J Assoc Physicians India.* 2004;52:591–3
- Davitt B, Gehrs K, Bowers T. *Endogenous Nocardia endophthalmitis.* *Retina* 1998; 18: 572–574
- Mamelak A. N., Obana W. G., Flaherty J. F., Rosenblum M. L. (1994). Nocardial brain abscess: treatment strategies and factors influencing outcome. *Neurosurgery* 35, 622–631.
- Phytinen J, Paakko E, Jartt P. Cerebral abscess with multiple rims on MRI. *Neuroradiology* 1997; 39: 857- 859. PMID: 94577009
- Davitt B, Gehrs K, Bowers T. *Endogenous Nocardia endophthalmitis.* *Retina* 1998; 18: 572–574

- Yildiz O., Doganay M. 2006; Actinomycoses and *Nocardia* pulmonary infections. *Curr Opin Pulm Med.* 12 :228. doi:http://dx.doi.org/10.1097/01.mcp.0000219273.57933.48. PubMed PMID: 20636427.
- Wilson J.W. 2012; Nocardiosis: updates and clinical overview. *Mayo Clin Proc.* 87 :403. doi:http://dx.doi.org/10.1016/j.mayocp.2011.11.016. PubMed PMID: 10795594.
- Wakhlu A, Agarwal V, Dabadghao S, Prasad KN, Nityanand S. Nocardiosis in patients of chronic idiopathic thrombocytopenic purpura on steroids. *J Assoc Physicians India.* 2004;52:591–3.
- Torres O.H., Domingo P., Pericas R., Boiron P., Montiel J.A., Vázquez G. 2000; Infection caused by *Nocardia farcinica*: case report and review. *Eur J Clin Microbiol Infect Dis.* 19 :205. doi: http://dx.doi.org/10.1007/s100960050460. PubMed PMID: 18003809.
- Ambrosioni J., Lew D., Garbino J. 2010; Nocardiosis: updated clinical review and experience at a tertiary center. *Infection.* 38 :89. doi:http://dx.doi.org/10.1007/s15010-009-9193-9. PubMed PMID: 20306281
- Gombert M.E., Berkowitz L.B., Aulicino T.M., duBouchet L. 1990; Therapy of pulmonary nocardiosis in immunocompromised mice. *Antimicrob Agents Chemother.* 34 :1766. doi: http://dx.doi.org/10.1128/AAC.34.9.1766. PubMed PMID: 21155087.
- Memelak AN, Obana WG, Flaherty JF, Rosenblum ML. Nocardial brain abscess: Treatment strategies and factors influencing outcome. *Neurosurgery.* 1994;35:622–31.
- Hardak E, Yigla M, Berger G, Sprecher H, Oren I. Clinical spectrum and outcome of *Nocardia* infection: experience of 15-year period from a single tertiary medical center. *Am J Med Sci.* 2012;343(4):286–290. doi: 10.1097/MAJ.0b013e31822cb5dc.
- Sorrell TC, Mitchell DH, Iredell JR. *Nocardia* species. U: Mandell GL, Bennett JE, Dolin R, ur. *Principles and Practice of Infectious Diseases.* 6th ed. Philadelphia: Churchill Livingstone; 2005, str. 2916–24.
- Eschle-Meniconi ME, Guex-Crosier Y, Wolfensberger TJ: *Endogenous ocular nocardiosis—an interventional case report with a review of the literature.* *Surv Ophthalmol* 2011,56(5):383–415. 10.1016/j.survophthal.2011.03.003
- Brown-Elliott BA, Brown JM, Conville PS, Wallace R.J., Jr Clinical and laboratory features of the *Nocardia* spp. based on current molecular taxonomy. *Clin Microbiol Rev.* 2006;19:259–282. doi: 10.1128/CMR.19.2.259-282.2006.