

**How to Cite:**

Moselhy, A. A., & Aly, N. (2022). Management of large maxillary defect: A case study. *International Journal of Health Sciences*, 6(S1), 9657–9665. <https://doi.org/10.53730/ijhs.v6nS1.7255>

# Management of large maxillary defect: A case study

**Ahmed Amin Moselhy, DDS, MS, PhD**

Assoc. Pr. in Military Medical Academy, Department of Maxillofacial Prosthodontic, Kopy El Koba Military Hospital, Egypt

**Nasser Aly, DDS, MS, PhD**

Assoc. Pr. Faculty of Oral and Dental Medicine, Badr University Egypt.

**Abstract**--In cases of large maxillary defects and trismus that result from surgical removal of a tumor in the maxilla, the use of two pieces obturator overcome the problem and improve retention of the obturator by engagement of all desirable undercuts which enhance retention of the obturator. Improve retention of the obturator help the patient to continue his/her life. The case study describes the construction of a two pieces obturator with silicon bulb attached to a hollow Bulb obturator by a ledge.

**Keywords**---Acrylic resin hollow obturator, silicon bulb, large maxillary defect, mouth rehabilitation.

## Introduction

Surgical removal of a tumor in the maxilla results in sever functional, aesthetic and psychological problems (1). Prosthetic rehabilitation of the case help restoration of most of these effects (2). Retention of the obturator is a challenge. The defect in the palate prevents peripheral seal and stability of the prosthesis (3). Engagement of bony undercuts in the defect is a very important factor to overcome the problem (3,4). Flexible materials have the ability to engage the bony undercuts without trauma to the remaining tissues. The two pieces obturator with flexible bulb permits the use of all bony undercuts in the defect without problem with the pass of insertion and removal of the obturator (5,6). This article explains an economic method for formation of a two pieces obturator.

## Material and methods

A 45-year-old male patient was referred to the Department of Prosthodontics at Kobry El Kobba Military Hospital, Cairo, Egypt, for the fabrication of obturator prosthesis. Oral examination revealed a large class IV but well healed defect on

the left side of the maxilla along with loss of teeth on the defect side side (Fig. 1). The silicone cap is first fabricated. Blocking of the airways with vaslinized gauze attached by stitches (Fig. 2). Impression of the defect was taken with putty body rubber base impression material (Zhermack- Zetaplus – Germany) in increments to be sure of recording of all undercuts in the defect (Fig. 3). Care was taken with application of Vaseline as a separating medium between increments to prevent binding of them. Each increment was attached to the other with press studs made by the hand of mirror (Fig. 4). The increments attached to each other outside the patient' mouth (Fig. 5), then the cast was poured (Fig. 6). Split of the cast was done to preserve all the undercuts (Fig.7) and reassembled (Fig. 8). The bulb of the defect was waxed and was tried in the patient' mouth (Fig. 9). A ledge was made in the waxed bulb for engagement of the processed silicon bulb with the acrylic part of the hollow obturator (Fig.10). Made a base for the cast with two sprues to be sure of complete packing of silicon after wax elimination (Fig. 11). The waxed bulb was Flashed, dewaxed and packing with heat temperature vulcanizing silicone (Preident – Germany) and curing (Fig. 12, 13, 14). Delivery of the silicon bulb in the palatal defect (Fig. 15). Impression for the maxilla with heavy body rubber base (Zhermack- Zetaplus – Germany). Then a pick-up impression of the silicon bulb from the defect was taken with wash layer light body rubber base (Zhermack- Zetaplus – Germany). Master cast was poured and Jaw relation recorded (Fig.16). Processing of the hollow acrylic obturator was done. The silicon bulb was attached to the hollow obturator by a ledge. (Fig. 17). Delivery of the two-piece obturator was done comfortably (Fig. 18).

## **Discussion**

Acquired defects may be due to trauma, pathologic causes or surgical removal of a tumor which is the most common cause. Trauma like gunshot, perforation of the soft and hard palate by sharp instrument (7), ill-fitting dentures. Disease like Tuberculosis of the palatal bone, Syphilis, and Osteomyelitis. Maxillofacial patients have functional, esthetic and psychological disorders. Functional disorders, As regards eating food, swallowing and speaking. Psychological disorders; as regards anxiety and depression and esthetic disorders as a result of the defect (1). Factors affecting the cancer surgical treatment plan for oral cancer patients include, prognosis and systemic status of patient; potential size and site of defect; potential nature of functional and/or cosmetic defect; adjunctive therapy (e.g., chemotherapy or radiation) that may compromise the surgical result; and anticipated changes to function and cosmetic, and cost of rehabilitative procedures (8,9). Two pieces obturator help to overcome the problems of retention and stability especially in case of large defects where engaging the bony undercuts in the palatal defect is very important solving these problems (5,6). A two pieces obturator with heat cured silicon bulb attached to a hollow acrylic obturator by a ledge was processed for a patient with large maxillary defect. This technique is cost-effective and useful.

## **Conclusion**

The prosthetic restoration of patients with large maxillary defect using two pieces obturator with flexible bulb improve retention and stability of the obturator and consequently regain to great extent the functional, aesthetic and psychological

well being and help the patient to continue his/her life. In this case study the large maxillary defect was restored with flexible silicon bulb attached to a hollow maxillary obturator by a ledge which provide an economically, comfortable and effective prosthetic restoration of the large defect. All the steps of the prosthetic restoration were start after the patient sign informed consent form.

## References

1. Srinivasan M. Rehabilitation of an acquired maxillary defect. *J Indian Prosthodontic*. 2005; 3:155–157.
2. Riaz N, Warriach RA. Quality of life in patients with obturator prostheses. *J Ayub Med Coll Abbottabad*. 2010; 22:121-125.
3. Oh WS, Roumanas ED. Optimization of maxillary obturator thickness using a double-processing technique. *J Prosthet Dent*. 2008; 17:60-63.
4. Devlin H, Barker GR. Prosthetic rehabilitation of the edentulous patient requiring a partial maxillectomy. *J Prosthet Dent*. 1992; 67:223-227.
5. Mishra N, Chand P, Singh RD. Two-piece denture-obturator prosthesis for a patient with severe trismus: A new approach. *J Indian Prosthodont. Soc*. 2010; 10:246-248.
6. Niraj Mishra, Pooran Chand, Raghuwar Dayal Singh. Two-Piece Denture-Obturator Prosthesis for a Patient with Severe Trismus: A New Approach. *J Indian Prosthodontic Soc*. 2010; 10:246–248.
7. Wu YL, Schaaf NG. Comparison of weight reduction in different designs of solid and hollow obturator prostheses. *J Prosthet Dent*. 1989; 62:214-217.
8. Borlase G. Use of obturators in rehabilitation of maxillectomy defects. *Ann R Australas Coll Dent Surg*. 2000; 15:75-79.
9. Kumar NS. Prosthetic rehabilitation of a complete bilateral maxillectomy patient: A technical report. *Aust J Basic Appl Sci*. 2009; 3:424-431.

**Figures**

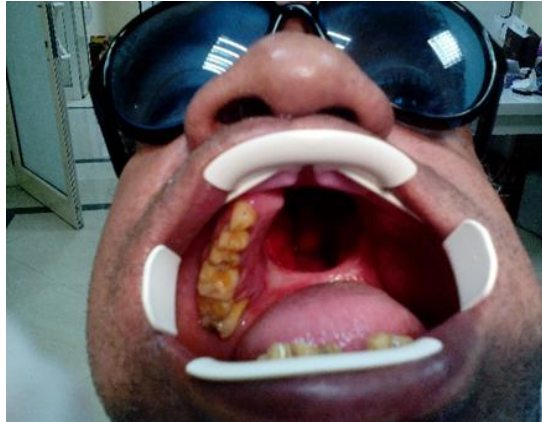

Figure 1: Class IV intraoral defect

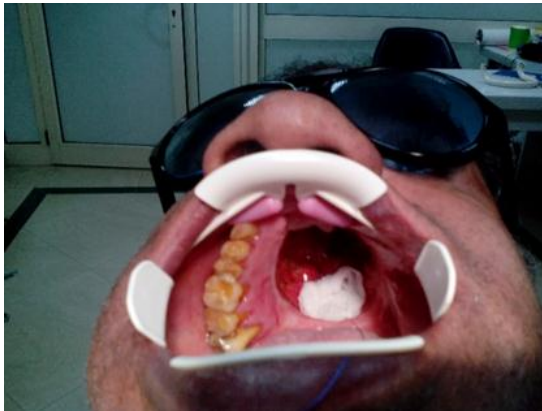

Figure 2: Blocking of the airways with vaslinized gauze

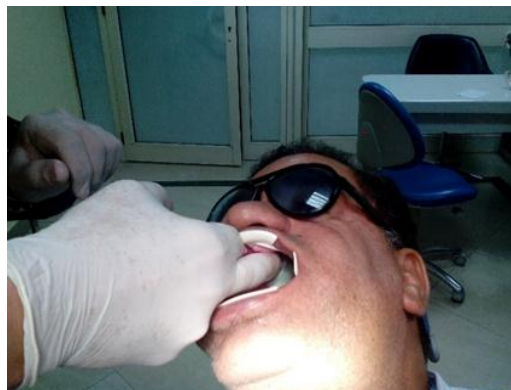

Figure 3: Impression of the defect was taken in increments to be sure of recording of all undercut in the defect

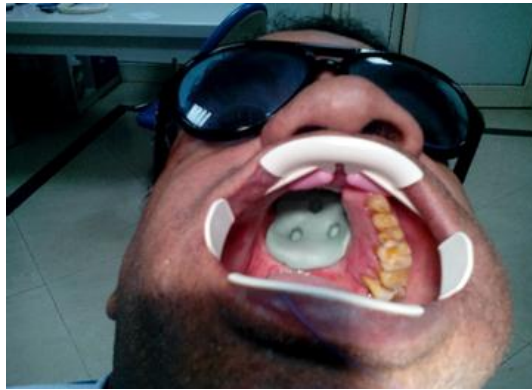

Figure 4: Each increment was attached to the other with press studs made by the hand of mirror



Figure 7: Split of the cast to preserve all the undercuts




Figure 8: Reassembling of the cast

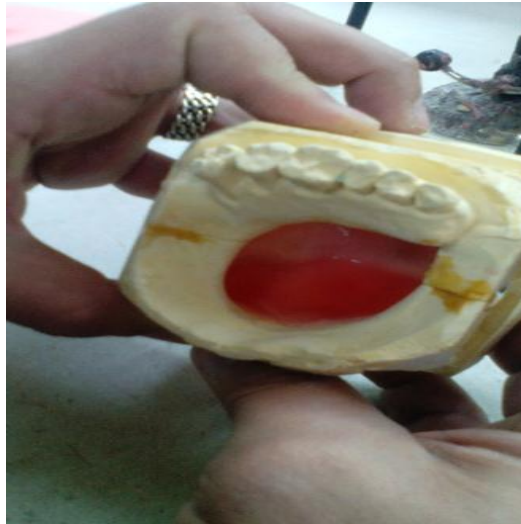

Figure 9: Waxing of the silicon bulb on the master cast

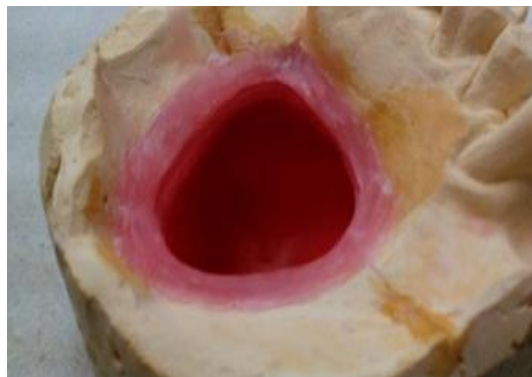

Figure 10: A ledge was made in wax for engagement of the silicon bulb to the hollow acrylic bulb of the obturator

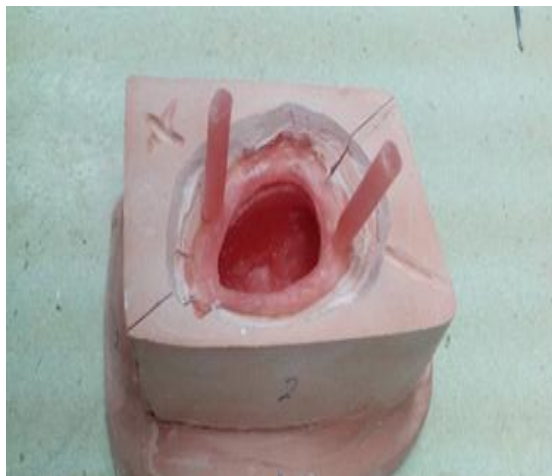

Figure 11: Two sprues were made to ensure complete packing of silicon

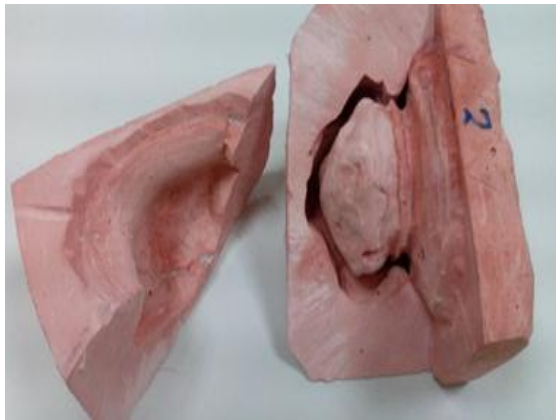


Figure 12: wax eliminated and all the undercuts preserved

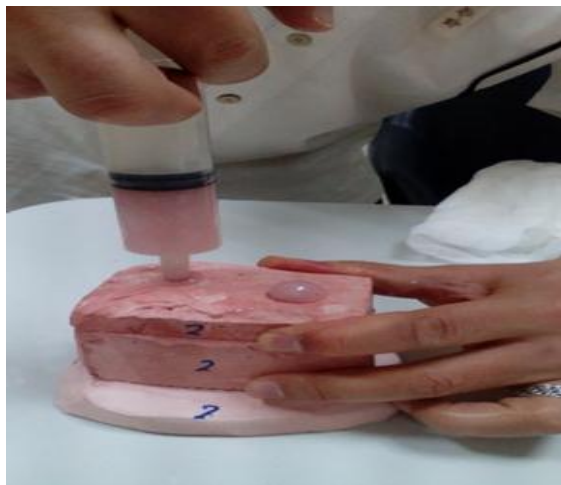

Figure 13: Packing of silicon

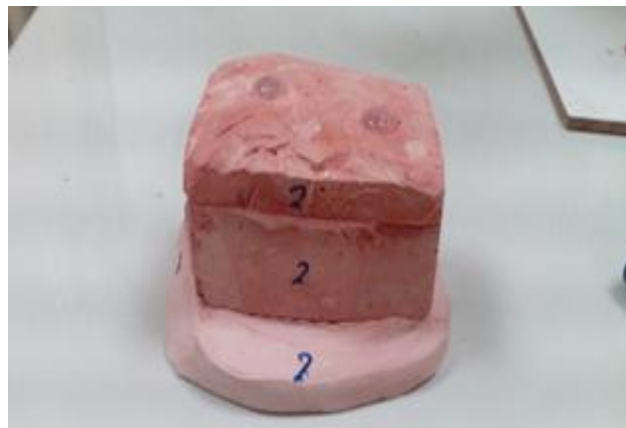

Figure 14: Packing of silicon completed

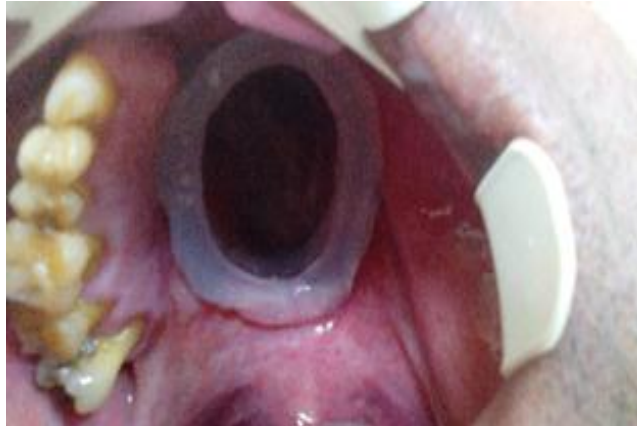

Figure 15: Delivery of the Silicone bulb in the palatal defect

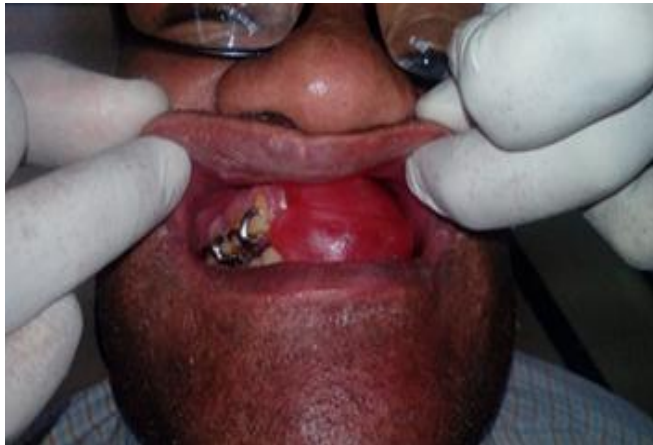

Figure 16: Jaw relation record

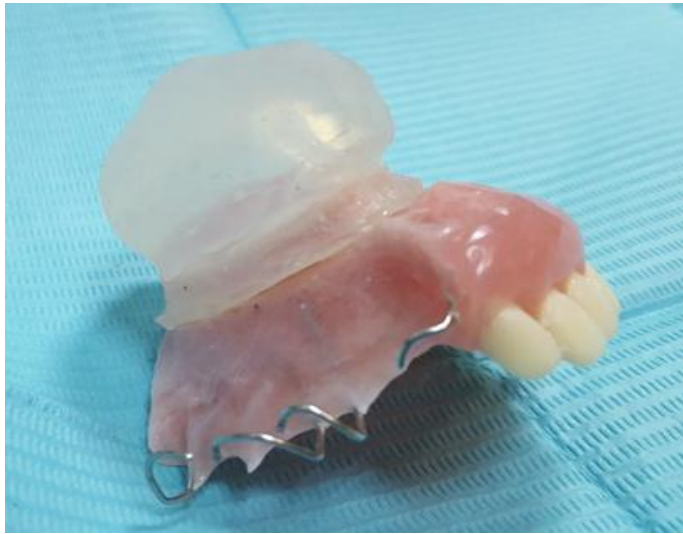

Figure 17: Silicone bulb attached by a ledge to the hollow maxillary obturator

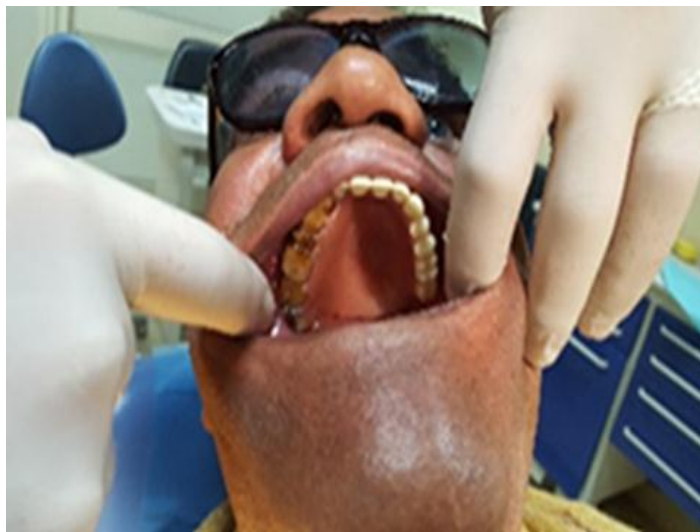

Figure 18: Delivery of the two-piece obturator