

**How to Cite:**

Ahuja, G., Waingkar, A. M., Singla, M., Singh, S., Dhurubatha, J., & Wadhawan, A. (2022). Clinical contemplation and management of multiple impacted canines: A case report. *International Journal of Health Sciences*, 6(S6), 10078–10086.  
<https://doi.org/10.53730/ijhs.v6nS6.12677>

## **Clinical contemplation and management of multiple impacted canines: A case report**

**Dr. Gaurav Ahuja**

Associate Professor, Department of Orthodontics and Dentofacial Orthopedics, Yamuna Institute of Dental Sciences and Research, Yamunanagar

**Dr. Akshay M. Waingkar**

Lt. Col Indian Army, Department of Orthodontics and Dentofacial Orthopedics. Government Dental Centre, Delhi Cantt, New Delhi

\*Corresponding author email: [urakshayw@gmail.com](mailto:urakshayw@gmail.com)

**Dr. Marry Singla**

Senior Lecturer, Department of Orthodontics and Dentofacial Orthopedics. SGRD Dental College, Amritsar

**Dr. Shikha Singh**

Professor and Head, Department of Orthodontics and Dentofacial Orthopedics, Rajasthan Dental College and Hospital, Jaipur

**Dr. Dhurubatha J.**

Post Graduate, Department of Oral and Maxillofacial Surgery, Government Dental College, Kadapa

**Dr. Ashutosh Wadhawan**

Associate Professor, Department of Orthodontics and Dentofacial Orthopedics, Swami Vivekanand Subharti University, Uttar Pradesh

**Abstract**--The impaction of the maxillary canines causes relevant a esthetic and functional problems. The multidisciplinary approach to the proper planning and execution of orthodontic traction of the element in question is essential. Many strategies are cited in the literature among the mis the good biomechanical control in order to avoid possible side effects. The aim of this paper is to present a case report in which a superior canines impacted by palatine was pulled out with the aid of direct traction with the help of elastics and arch wires. A 19-year-old male patient reported with a chief complaint of malaligned teeth and missing some teeth. The proposed treatment prioritized the traction of the upper right canine without changing the occlusion and aesthetics. For this, straight wire appliance with .022

slot was inserted in order to minimize unwanted side effects. The use of cantilever to the traction of the upper right canine has enabled an efficient and predictable outcome, because it is of statically determined mechanics. Comprehensive orthodontic therapy along with surgical exposure of 13, 33 and 43 helped in achieving all the treatment objectives to great satisfaction without any adverse effects on the periodontium or the dentition. This case report details the diagnosis and clinical management.

**Keywords**--clinical, contemplation, management, multiple impacted canines.

## **Introduction**

Facial harmony is directly associated with the presence of canines in the dental arch, which are important for stable occlusion<sup>1</sup>. However, tooth impaction can be one of the factors responsible for the aesthetic and functional imbalance. In particular, the incidence of impaction of the upper canines ranges from 1% to 3%<sup>2</sup>. Some etiological factors may justify the retention and/or impaction of the canine, as the long path that runs to its full eruption associated with the fact that is the last tooth to erupt in chronological order, besides genetic factors, atresic arcade, trauma, and consequences of systemic diseases<sup>1,3</sup>. The impaction of maxillary canines occurs most frequently by palatine (85% against 15% in the buccal region). For a correct diagnosis and development of the treatment plan, it is essential to define the tooth location. Thus, it is essential to perform a detailed clinical examination, associated with radiographic and/or computed tomography.

Clinical signs observed in cases of impaction are prolonged retention of deciduous canine, delayed eruption of the permanent canine and, depending on the position of the canine included, Absence of vestibular bulging, presence of palatal bulging, and distal slope of the maxillary lateral incisor crown and may present, or not, midline deviation<sup>4</sup>. The orthodontic treatment should be started as soon as possible to avoid secondary problems<sup>5</sup>. One of the most suitable procedures is orthodontic traction, and its success is directly linked to the management of side effects. Therefore, biomechanical knowledge is required to choose an ideal system of forces for each intended movement<sup>6</sup>. The procedures used for surgical exposure and traction are important in any impaction case<sup>7,8</sup> but a buccally impacted canine is especially problematic. If the tooth is positioned high in the alveolus, full-thickness flap surgery is generally required to expose the crown.

After an appropriate attachment is placed for traction, the flap can be repositioned and sutured either in the same location or apical to the cemento-enamel junction. Although the level of periodontal reattachment does not seem to significantly affect the clinical outcome, apical repositioning appears to be an inferior choice from an esthetic perspective.<sup>9,10</sup> If the impacted canine is more occlusally positioned, it is usually preferable to close the flap in its original position, with orthodontic traction obtained by attaching a ligature wire or elastic chain to the archwire. Although this approach promotes tissue healing, it does have several drawbacks, including the need for frequent reactivation. In addition,

the submucosal portion of a ligature wire or traction chain sometimes fractures, necessitating further surgery, and the resistance offered by the impacted canine often causes displacement of the adjacent teeth. An effective solution is to apply light, direct traction from an orthodontic wire deflected close to the impacted tooth and then completely covered by the flap, which is repositioned in its original location. The canine thus undergoes coronobuccal traction in the direction of the adjacent crowns. This method not only allows optimal soft-tissue healing, but also encourages better oral hygiene due to the absence of wires or elastic chains, which are excellent plaque receptacles. Furthermore, it reduces the likelihood of breakage that might require re-exposure of the tooth. The present article shows a patient treated with this technique.

### **Case report**

#### **chief complaint, history, clinical features, radiographic and other investigation findings**

A 19-year-old male patient reported with a chief complaint of malaligned teeth and missing some teeth. There was no other relevant medical history related to the canine impaction. Clinical examination showed symmetrical and proportional face, straight and harmonious profile, passive lip closure, suitable smile line (Fig. 1a and 1b). The vertical facial proportions is normal, convex facial profile, competent, non protrusive lips (Fig. 1c). Angles Class I occlusion on both sides (Fig. 2a and 2b), matching media lines, normal overjet and overbite, with mixed dentition with presence of the element 73 and 83, and the absence of their successor 13, 33,43 (Fig. 3a, 3b and 3c). There was an excessive show of upper incisors along with a gummy smile (Fig. 1b). Intraoral examination revealed exaggerated canine fossa due to absence of root prominence of 13, exaggerated root prominence of 12, 14, and all upper anterior teeth, irregular gingival contours of 11, 12, 21, 22, 23 with increased thickness of attached gingiva and presence of pseudo pockets (Fig. 3 a).

The oral hygiene was fair. All teeth except 13,33,43 were present(Fig. 3 a, 3b and 3c). Upper third molars are absent and lower third molars were partly erupted (Fig. 4). Orthodontic evaluation revealed 8 mm spacing in upper arch and 2 mm spacing in lower arch. Occlusal evaluation revealed an overjet of 1.5 mm and an overbite of 2.5 mm. The upper midline was shifted to the right and lower shifted to the left. Angle's Class I molar relation on both sides were present. The tooth number 14 and 32 was rotated distally. There were asymmetric upper and lower arch forms. There was a reverse curve of Spee in upper arch causing a pseudo-deep bite. There were wear facets on palatal cusp of 32, 42 showed slight rotation. The upper midline was shifted to the right with respect to the anterior nasal spine (ANS). Model analysis indicated an Ashley Howe's index of 37% suggesting that there is no need of extraction in this case. Tooth-size analysis indicated average sized upper and lower total tooth material.. Bolton's analysis suggested normal proportions (while calculating we assumed an equal width of 13, 23,33,43). Radiographs confirmed the diagnosis and also revealed the presence of a small supernumerary tooth, rotated with its crown in an apical position, which had probably impeded the eruption of the permanent canine in first, third and fourth quadrant (Fig. 4).

## Diagnosis

The 19-year-old patient presented with a dental Class I and a skeletal Class II base with a vertical growth pattern. The upper and lower anteriors were retroclined. There was a palatally positioned horizontally impacted 13 and vertically impacted 33 and 43. There was mild maxillary asymmetry due to a depressed upper right canine region with asymmetric upper and lower arch forms and deviated midlines. There was upper and lower dental spacing a pseudo-deep bite. The upper anterior gingival contours were irregular with pseudopockets and increased attached gingival heights. There was mild rotation of 14, 32. The oral hygiene was fair. The soft tissue profile was acceptable.

## Treatment plan and prognosis

Despite the difficulty involved in treating, in time and effort, the unfavorably positioned 13,33,43 the treatment of choice was to attempt to save it for the following reasons.

- Absence of canine eminence resulted in a depressed facial appearance of the upper right canine region. It was assumed that by sufficient labial torque application to the canine root after alignment, at least some alveolar support could be regained.
- A shorter treatment plan against the selected plan would have been to extract the impacted canines and restore the missing canines with a prosthodontic dental implant. The oral surgeon opined that bone graft would be additionally required to place the implant with an optimum inclination. However, the patient refused the same.
- The patient was well aware of the difficulty and time involved in correcting the canine impaction and assured his cooperation towards his preferred mode of treatment.
- Deep bite would be corrected by intrusion of the upper anterior and by correcting the inclinations of the upper and lower anteriors. This was favored by the increased nasolabial angle and the negative lip strain at pretreatment (Table 1).

No extractions were required. The treatment plan involved the use of 0.022 (McLaughlin Bennett Trevisi) MBT prescription metal preadjusted straight wire appliance. The planned archwire sequence started with .014", .016" and .018" Damon Copper NiTi wires, followed by .018", .016" x .022", .017" x .025", .019 x .025 Damon stainless steel wires. Surgical exposure of impacted 13,33,43 using the palatal flap technique was planned. Care was to be taken to ensure that there were no adverse effects on the roots of the teeth or on the periodontium in course of the prolonged treatment duration. Once the canine would be in alignment, the lack of spaces in upper arch, proper interincisal relations, idealized arch forms, good cusp-fossa interrelationship, and harmonious soft tissue balance would help in leading to a good prognosis for stability.

### **Treatment progress**

After two months of treatment, sufficient space had been obtained for the maxillary right canine. A vestibular flap was opened to expose the canine and allow removal of the supernumerary, and a minitube was bonded to the labial surface of the impacted tooth. An .014" Copper NiTi segmental wire was then inserted in the horizontal auxiliary bracket slots from the maxillary right first molar to the left lateral incisor, deflected toward the impacted canine, and tied to the bonded minitube with .009" ligature wire (Fig. 5a). The flap was repositioned in its original location and sutured with 3.0 silk sutures. To maintain the canine space and prevent any inclination of the adjacent teeth during traction, an open-coil spring was threaded onto the .018" × .025" Copper NiTi main archwire (Fig. 5b). After another three months of the treatment the 73 and 83 are extracted and periosteal flap was opened to expose 43 and lingual button is 43 with attached elastic on 43 for the traction of 43 (Fig. 6). Over the next six months, the progress of canine eruption was evaluated monthly. No complications were observed at the surgical site, and the gingivae remained healthy. Once sufficiently erupted, the crown of the impacted canine was bonded with a canine bracket to finish the occlusion. The total duration of treatment was 27 months (Fig. 7, Fig. 8 and Table 1).

### **Discussion**

Fournier and colleagues recommended that a labially impacted tooth in a favorable vertical position should be surgically exposed without the application of orthodontic traction in a young patient, whereas immediate traction is almost always needed in an adult patient.<sup>11</sup> Other authors have stated similar opinion regarding palatally impacted canines<sup>12</sup> in particular, Schmidt and Kokich observed that surgical exposure and free eruption are preferable to closed exposure and early traction.<sup>13</sup> Labial impaction, on the other hand, is generally thought to be more difficult to manage,<sup>14,15</sup> although some surgeons use the vertical and horizontal position of the impacted tooth and the quantity of the surrounding gingiva as guidelines.<sup>16,17</sup> Before determining the appropriate intervention, the esthetic and functional sequel i.e. gingival attachment, height, width, scarring, clinical crown length, and relapse potential must be carefully evaluated.<sup>9</sup> One point of agreement by many authors is that a lack of attached gingiva around the erupting canine can lead to inflammation and serious periodontal consequences during orthodontic traction. For this reason, many prefer to close the flap in its original position after exposure of the tooth and attachment of a traction button, thereby ensuring adequate gingival tissue around the canine. Other clinicians prefer to perform a partial-thickness flap and to reposition it apically so as to cover the cement enamel junction and 2-3mm of the crown, thus preventing marginal bone loss and gingival recession.<sup>18</sup>

### **Conclusion**

The alternative method presented here applying direct orthodontic traction with a light wire rather than attaching a metal ligature or elastic chain from the archwire pulls the crown of the impacted tooth in a buccal direction for more favorable realignment. It also promotes good hygiene at the affected site, minimizing the

risk of mucosal inflammation. Constant traction from the round Copper NiTi segmental wire avoids the need for subsequent reactivations. A bond failure of the button or bracket on the impacted tooth could require further surgery, as with other traction procedures, but there is no concern about breakage of traction wires or elastic chains.

Table 1  
Pretreatment and posttreatment cephalometric findings as per Indian board of orthodontics requirements Indian board of orthodontics cephalometric analysis (adjusted for magnification)

Variable	Normal	Pretreatment (A)	Posttreatment (B)
<b>SAGITTAL SKELETAL RELATIONSHIP:</b>			
SNA	82	84.1	81
SNB	80	78	77
ANB	2	6	4
Wits appraisal	0-1mm	6mm	5mm
<b>DENTAL BASE RELATIONSHIP:</b>			
Upper incisor to NA (mm/deg)	4.22mm	-1.7mm	5.31mm
Lower incisor to NB (mm/deg)	4.25mm	7mm	8mm
Upper incisor to SN plane	103 <sup>o</sup>	91.5 <sup>o</sup>	112 <sup>o</sup>
Lower incisor to MP angle (IMPA)	90-100	91	95
<b>DENTAL RELATIONSHIP:</b>			
Interincisal angle	131	139	113
Lower incisor to APo line	2mm	1.5mm	6mm
Overbite	2mm	4.5mm	1.5mm
Overjet	2mm	1.5mm	1.5mm
<b>VERTICAL SKELETAL RELATIONSHIPS:</b>			
Maxillary-mandibular planes angle	25	29	31
SN plane-mand plane	32	33	35
Upper anterior face height	45mm	57mm	58.5mm
Lower anterior face height	55mm	75mm	77mm
Face height ratio	82%	76%	76.5%
Jarabak ratio	62-64%	63.5%	62%
Maxillary length (McNamara)		112mm	110.5mm
Mandibular length-effective		135mm	136.5mm
<b>SOFT TISSUES:</b>			
Lower lip to Ricketts E plane	-2mm	1mm	1.5mm
Nasolabial Angle	90-110	120	114

## References

1. Abdulwadood, T. E., & Alradhi, M. S. H. (2022). Randomized clinical trial (RCT) of a clinical pharmacist intervention to reduce drug misuse and improve inappropriate prescribing in hospitalized patients in province of Al Basra. *International Journal of Health Sciences*, 6(S2), 12845-12852. <https://doi.org/10.53730/ijhs.v6nS2.8388>

2. Alqahtani H. Management of maxillary impacted canines: A prospective study of orthodontists' preferences. *Saudi Pharm J.* 2021;29(5):384-390.
3. Bishara, S.E.: Impacted maxillary canines: A review. *Am. J. Orthod.* 1992;101:159-171.
4. Burden, D.J. Mullally B.H. and Robinson S.N. Palatally ectopic canines: closed eruption versus open eruption, *Am. J. Orthod.* 1999;115:640-644.
5. C.A. Frankand and M.Long. Periodontal concerns associated with the orthodontic treatment of impacted teeth. *American Journal 6 Case Reports in Dentistry of Orthodontics and Dentofacial Orthopedics* 2002 ; 121(6):639649.
6. Fournier, A Turcotte, J.Y and Bernard C. Orthodontic considerations in the treatment of maxillary impacted canines, *Am. J. Orthod.*1982; 81:236-239.
7. Grisar K, Fransen J, Smeets M, Hoppenreijts T, Ghaeminia H, Politis C, Jacobs R. Surgically assisted orthodontic alignment of impacted maxillary canines: A retrospective analysis of functional and esthetic outcomes and risk factors for failure..*Am J Orthod Dentofacial Orthop.* 2021;159(6):461-471.
8. Grisar K, Piccart F, Al-Rimawi AS, Basso I, Politis C, Jacobs R : Three-dimensional position of impacted maxillary canines: Prevalence, associated pathology and introduction to a new classification system..*Clin Exp Dent Res.* 2019;5(1):19-25.
9. Grisar K, Piccart F, Al-Rimawi AS, Basso I, Politis C, Jacobs R. Three-dimensional position of impacted maxillary canines: prevalence, associated pathology and introduction to a new classification system. *Clin Exp Dent Res.* 2019;5(1):19-25.
10. J.N. Eleftheriadis and A.E. Athanasiou. Evaluation of impacted canines by means of computerized tomography. *The International Journal of Adult Orthodontics and Orthognathic Surgery* 1996;11(3):257-264.
11. Kohavi D, Zilberman Y and Becker A. Periodontal status following the alignment of buccally ectopic maxillary canine teeth. *Am. J. Orthod* 1984;85:78-82.
12. Kokich V.G. and Mathews D.P. Surgical and orthodontic management of impacted teeth, *Dent. Clin. N. Am.* 1993; 37:181-204.
13. Kufteinec M.M. and Shapira Y. The impacted maxillary canine: I. Review of concepts, *ASDC J. Dent. Child.* 1995; 62:317-324.
14. Lewis, P.D. Preorthodontic surgery in the treatment of impacted canines. *Am. J. Orthod.* 1971;60:382-397.
15. M. A. P. Maahs and T. B. Berthold. Etiological diagnostic o e tratamento de caninos superiores permanentes impactados. *RevistadeCi^ encias M^edicaseBiol^ogicas* . 2004; 3(1):130-138.
16. Motamedi MH, Tabatabaie FA, Navi F, Shafeie HA, Fard BK, Hayati Z. Assessment of radiographic factors affecting surgical exposure and orthodontic alignment of impacted canines of the palate: a 15-year retrospective study. *Oral Surg Oral Med Oral Pathol Oral Radiol Endod.* 2009;107(6):772-5.
17. N.Cohenca, J.H.Simon, A.Mathur, and J.M.Malfaz. Clinical indications for digital imaging in dento-alveolar trauma. Part2: root resorption. *Dental Traumatology* 2007; 23( 2):105-113.
18. Ngan P Hornbook R.; and Weaver, B.: Early timely management of ectopically erupting maxillary canines, *Semin. Orthod.* 2005;11:152-163.

19. Nur, I. L., Ahmad, M., Syarif, S., & Ahmar, H. (2021). The performance of midwives in managing childbirth using a digital partograph. *International Journal of Life Sciences*, 5(2), 26–35. <https://doi.org/10.29332/ijls.v5n2.1219>
20. S. E. Bishara and D. Ortho. Impacted maxillary canines: a review. *American Journal of Orthodontics and Dentofacial Orthopedics* 1992 ;101(2):159-171.
21. S. F. Dachi and F. V. Howell. A survey of 3,874 routine full mouth radiographs. A study of retained roots and teeth. *Oral Surgery, Oral Medicine, Oral Pathology* 1961; 14( 8): 916- 924.
22. Schmidt, A.D. and Kokich V.G. Periodontal response to early uncovering, autonomous eruption, and ortho dontic alignment of palatally impacted maxillary canines. *Am. J. Orthod.* 2007;131:449455.
23. Suryasa, I. W., Rodríguez-Gámez, M., & Koldoris, T. (2021). The COVID-19 pandemic. *International Journal of Health Sciences*, 5(2), vi-ix. <https://doi.org/10.53730/ijhs.v5n2.2937>
24. Vanarsdall, R. and Corn, H. Soft-tissue management of labially positioned unerupted teeth, *Am. J. Orthod.* 1977;72:5364.
25. Vermette M.E, Kokich, V.G. and Kennedy, D.B.: Uncovering labially im pacted teeth: Apically positioned flap enclosed-eruption techniques. *Angle Orthod.* 1995;65:23-32.
26. Von der Heydt, K. The surgical uncovering and orthodontic positioning of unerupted maxillary canines, *Am. J. Orthod.* 1975;68: 256-276.

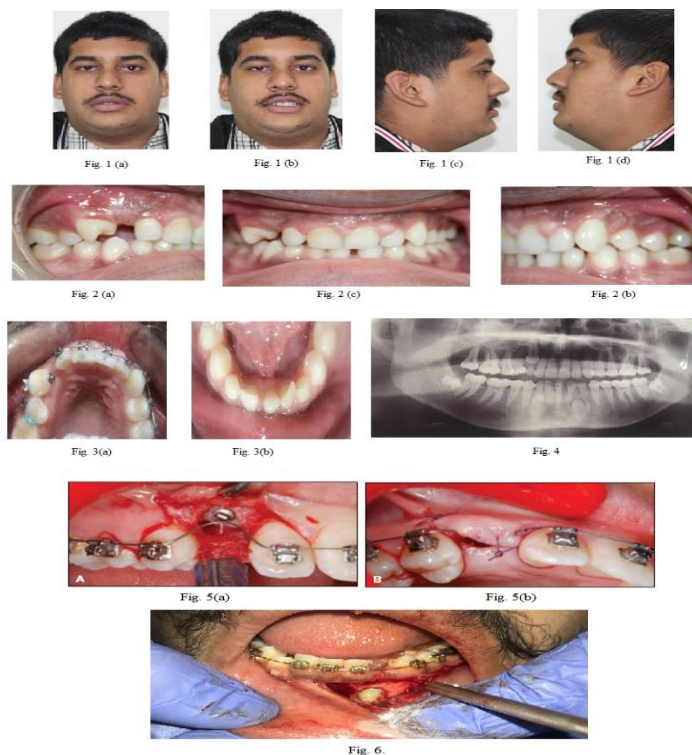


Fig. 1-6. Surgical exposure of upper canine (13) and surgical exposure of lower canine (43)

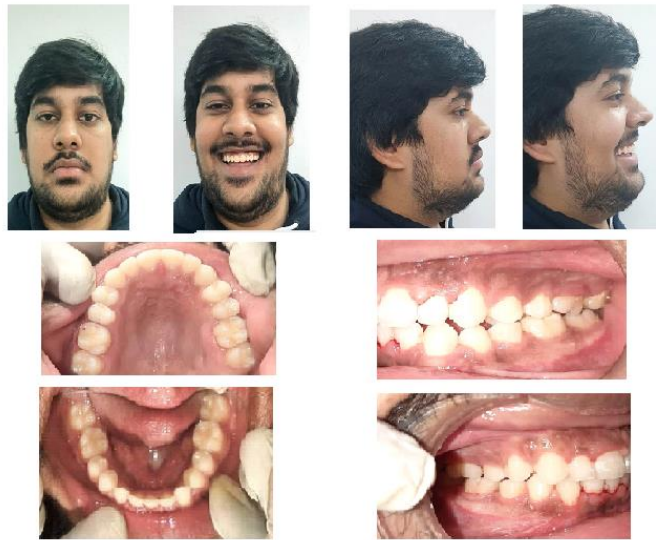

Fig. 7. Post treatment photographs – extraoral and intraoral




Fig. 8. Post treatment superimpositions: black line – pre treatment and red line – post treatment