

**How to Cite:**

Bhat, S., & Periasamy, S. (2021). Prevalence of juxta-apical radiolucency and its association to inferior alveolar nerve injury during removal of impacted mandibular third molars. *International Journal of Health Sciences*, 5(S2), 373–384.  
<https://doi.org/10.53730/ijhs.v5nS2.5860>

## **Prevalence of juxta-apical radiolucency and its association to inferior alveolar nerve injury during removal of impacted mandibular third molars**

**Swetha Bhat**

Department of Oral and Maxillofacial Surgery, Saveetha Dental College, Saveetha Institute of Medical and Technical Science, Saveetha University, Chennai 77.  
Email: [swethavb95@gmail.com](mailto:swethavb95@gmail.com)

**Senthilnathan Periasamy**

Department, Department of Oral and Maxillofacial Surgery, Saveetha Dental College, Saveetha Institute of Medical and Technical Science, Saveetha University, Chennai 77  
Email: [senthilnathan@saveetha.com](mailto:senthilnathan@saveetha.com)

**Abstract**--This study aimed to investigate the prevalence of juxta-apical radiolucency (JAR)- a well-defined area of radiolucency that is apical or lateral to the roots of the lower third molar. , and assessing its association to injury of the inferior alveolar nerve (IAN) during surgical removal of lower third molars. We evaluated 1250 panoramic radiographs and 1960 third molars for the presence of JAR. The patients were assessed based on the presence or absence of JAR. These were further classified according to the impacted third molar's angulation in relation to the adjacent second molar. The radiographic relationship of the mandibular canal and third molar was also noted. JAR was identified in 88 patients (4.4%). Out of the 88, 28 (31.8%) were males and 60 (68.1%) were females, which was statistically significant ( $P < 0.02$ ). There also was an association with teeth that were mesioangularly impacted which was not statistically significant. Radiographic signs of proximity to the mandibular canal were present in 48 (54.5%) of JAR cases. One (1.13%) of them reported with inferior alveolar nerve injury after the surgical procedure postoperatively. JAR was prevalent in 4.4% patients. It was more prevalent in females and is more commonly found in association to mesioangularly impacted lower third molars. These findings may help evaluate and guide recommendations for surgical treatment of patients at high risk of injury to the inferior alveolar nerve during removal of 3rd molars.

**Keywords**---third molars, impaction, juxta apical radiolucency, inferior alveolar radiolucency, nerve injury, paresthesia.

## **Introduction**

Surgical extraction of impacted mandibular third molars is a common procedure in dental practice [1]. It is usually a fairly simple procedure but has various complications. Proper planning in third molar surgery is one of the keys to preventing Tran- and post P surgical complications such as dry socket, pain, infection, and, especially, nerve damage [2–4]. Preoperative assessment of mandibular third molars should consider morphology, angulation, and relationship to adjacent structures (mandibular canal and cortical plates) [5–9]. Injury to the inferior alveolar nerve (IAN) is a rare, undesirable complication of surgical removal of lower third molars. It generally manifests as a neurosensory disturbance of the regions supplied by the third branch of the trigeminal nerve, and can have debilitating effects [10]. The overall risk ranges from 1% to 5%, and most injuries result in temporary hypoaesthesia of the lip and chin [11,12]. Several risk factors are associated with injury to the nerve during third molar surgery, the most important predictor of which may be the anatomical relation between the lower third molar and the inferior alveolar canal (IAC) [10,13].

Panoramic radiography is the standard imaging technique used for the preoperative evaluation of 3rd molars. Darkening of the roots, interruption of the white line of the IAC, and diversion of the canal, have previously been identified on panoramic radiography as being associated with an increased risk of injury to the IAN after removal of 3rd molars [14–16]. However, in 2005 a new one, “juxta apical area” (JAA) or “juxta-apical radiolucency” (JAR), was introduced [2]. On plain radiography it is presented as a well-defined area of radiolucency that is apical or lateral to the roots of the lower third molar, which often overlap the canal and interrupt its white line. The JAR appears as a hypodense area adjacent (juxta = meaning near, nearby, or close) to the apices and roots of mandibular third molars and has been considered a variation of the normal aspect of the trabecular bone in this region [17].

Despite JAR being a radiographic sign suggestive of the risk of injury to the IAN during third molar surgery, the literature on JAR is scarce. Previously our team has a rich experience in working on various research projects across multiple disciplines [18–32] Now the growing trend in this area motivated us to pursue this project. Therefore, the purpose of this study is to investigate the prevalence of juxta-apical radiolucency (JAR), and assessing its association to injury of the inferior alveolar nerve (IAN) during surgical removal of lower third molars

## **Materials and Methods**

### **Study set up**

This Prospective clinical study consisted of evaluation of 1250 panoramic radiographs and 1960 third molars for the presence of JAR in patients who reported to the department of oral and maxillofacial surgery, Saveetha Dental

College and Hospital, Chennai from June 2019 to March 2021 for the surgical removal of impacted mandibular third molar.

- Preoperative
 

The patients were classified into two groups based on the presence or absence of JAR. Subsequently, 2 groups with the same number of teeth and patients were arranged: the JAR group, composed of all cases of JAR in the sample, and the control group, composed of randomly selected cases without JAR. These teeth were evaluated according to the following parameters:

  - Angulation: Third molar angulation was evaluated according to the Winter classification (vertical, horizontal, mesioangular, or distoangular).
  - Depth of impaction: The depth of impaction of the third molars in relation to bone was classified as unerupted, partially erupted, or erupted.

The radiographic relationship of the mandibular canal and third molar was also noted.

Clinical variables were age, gender, smoking habit, history of pericoronitis
- Postoperative
 

The primary outcome variable was permanent neurosensory disturbance that was reported within or 6 months after the operation. In all cases, patients were reviewed, sutures were non-resorbable, and analgesics with antibiotics were prescribed routinely after operation.

### **Selection criteria**

Inclusion criteria:

- Patients requiring surgical removal of impacted mandibular third molars for either prophylactic reasons or therapeutic reasons
- Patients with either partial or complete bony impaction of mandibular third molars, irrespective of the angulation.
- Enrolment in the study was limited to patients of both genders under 40 years of age.

Exclusion criteria:

- The presence of a carious lesion
- Large restorations
- Endodontic treatment
- Other pathologies, including cysts or tumors of the third molars.

### **Study parameters**

- Age of the patient
- Gender of the patient
- Presence or absence of JAR
- Angulation and depth of the impacted tooth
- Radiographic relationship of the mandibular canal and third molar
- Permanent neurosensory disturbance - Inferior alveolar nerve injury

## **Data collection**

The data related to the stay parameters were obtained from among the patients who reported to the Department of Oral and Maxillofacial Surgery, Saveetha Dental College, Chennai from June 2019 to March 2021. An approval for the designed study was obtained from the Institutional Ethical Committee of Saveetha University. An informed verbal and written consent was obtained after explaining the nature of the procedure and the potential complications involved.

## **Data analysis**

The IBM SPSS (version 23.0) software was used to tabulate and analyse the collected data. Non parametric data was analysed using descriptive statistics measuring frequency and percentage.

## **Results**

### **Demographic distribution**

Out of the total 1250 panoramic radiographs and 1960 third molars evaluated, JAR was identified in 88 patients (4.4%). Out of the 88, 28 (31.8%) were males and 60 (68.1%) were females. It was significantly associated with female patients [Figure 1] and was prevalent in the second and third decades of life with a mean age of  $24 \pm 3.2$  years.

### **JAR**

JAR was identified in 88 patients (4.4%) out of the 1250 panoramic radiographs and 1960 third molars we evaluated.

### **Angulation (winters classification)**

Out of the total 88 patients with JAR, 58 (65.9%) were mesioangular, 18 (20.4%) were vertical, 9 (10.2%) were Horizontal and 3 (3.4%) disto angularly impacted. This showed that the presence of JAR was more prevalent in mesioangularly impacted molar which was statistically significant ( $P < 0.05$ )

### **Depth of impaction**

Out of the total 88 patients with JAR 19 (21.6%) were unerupted, 59 (67.04%) were erupted and 10 (11.37%) were erupted.

### **Neurosensory disturbance of inferior alveolar nerve**

Out of the total 88 patients, 48 (54.5%) present proximity to inferior alveolar nerve radiographically. Whereas 40 (45.5%) showed no nerve proximity of the impacted molar to the nerve. One (1.14%) patient with JAR reported back with paresthesia after the surgical procedure postoperatively.

| Parameters                          | JAR group   | Control group |
|-------------------------------------|-------------|---------------|
| Gender                              | 28 (31.8%)  | 42 (47.7%)    |
| Male                                | 60 (68.1%)  | 46 (52.3%)    |
| Female                              |             |               |
| Angulation (Winters classification) |             |               |
| Vertical                            | 18 (20.4%)  | 22 (25%)      |
| Mesioangular                        | 58 (65.9%)  | 40 (45.45%)   |
| Horizontal                          | 9 (10.2%)   | 20 (22.7%)    |
| Distoangular                        | 3 (3.4%)    | 6 (6.8%)      |
| Depth of impaction                  |             |               |
| Unerupted                           | 19 (21.6%)  | 16 (18.2%)    |
| Partially erupted                   | 59 (67.04%) | 65 (73.8%)    |
| Erupted                             | 10 (11.37%) | 7 (7.9%)      |
| Radiographic proximity to IAN       |             |               |
| Present                             | 48 (54.5%)  | 26 (29.5%)    |
| Absent                              | 40 (45.5%)  | 62 (70.5%)    |
| Neurosensory disturbance            |             |               |
| Present                             | 1 (1.14%)   | 0             |
| Absent                              | 87          | 88            |

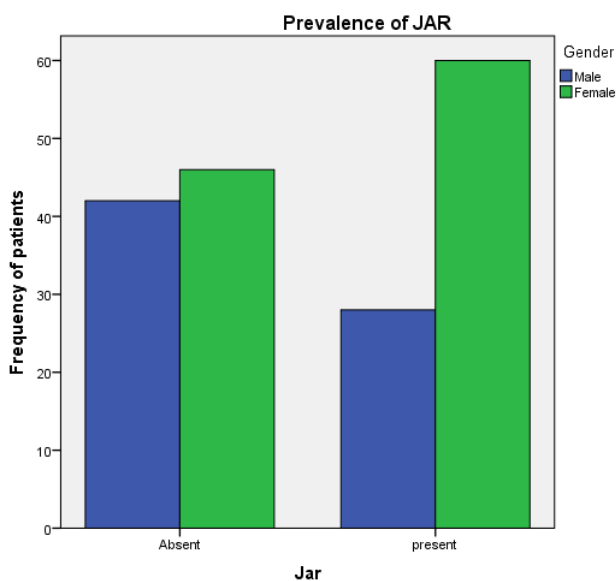


Figure 1. The above bar graph represents the association of gender to the prevalence of JAR. X axis represents the presence of absence of JAR, Y axis represents the frequency of patients. From this graph we can infer that 60 (68.1%) were females in comparison to 28 (31.8%) males. This difference was statistically significant ( $P=0.02$ )

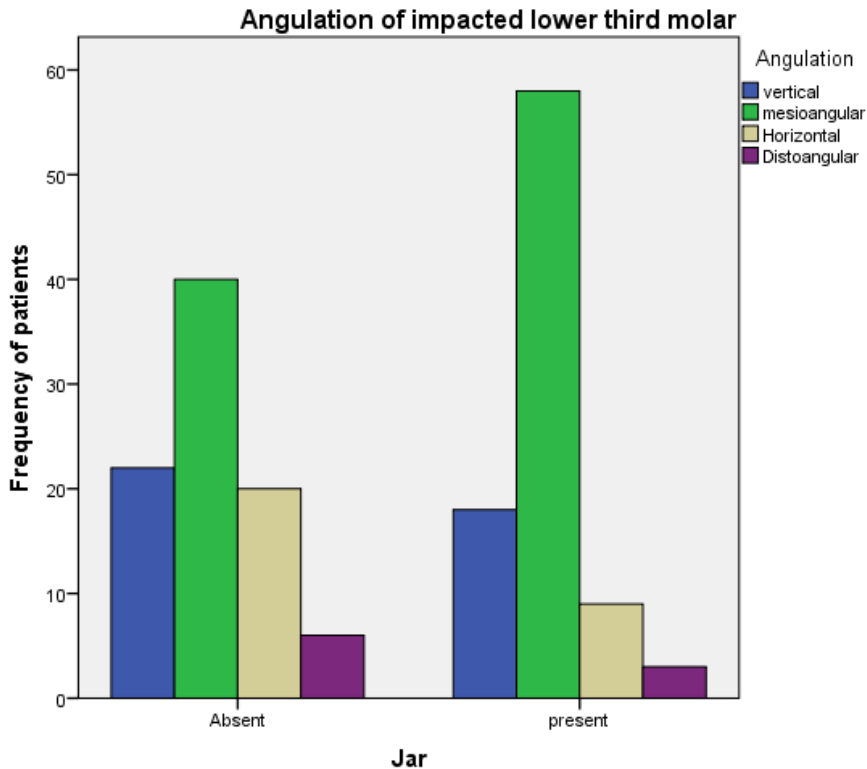


Figure 2. The above bar graph represents the association of angulation of the impacted lower molar to the prevalence of JAR. X axis represents the presence of absence of JAR, Y axis represents the frequency of patients. From this graph we can infer that 58 (65.9%) were mesioangularly impacted. This difference was statistically significant ( $P=0.03$ )

## Discussion

Panoramic radiographic imaging is currently the most frequently employed technique to evaluate the risk of nerve injury following extraction of an impacted mandibular third molar [1]. In this context, the panoramic radiograph stands out as a valuable imaging choice because it shows tooth morphology, tooth angulation, and radiographic signs of proximity to the mandibular canal, all of which are delivered with low radiation doses and at low cost [8,33]. Preoperative identification of potential risk factors for IAN exposure or injury is essential for safe surgical treatment of the mandibular third molars [4]. The risk of inferior alveolar nerve injury is evaluated based on radiographic evidence of an intimate anatomic relationship and proximity present between the third molar and the inferior alveolar nerve canal.

The juxta-apical radiolucency (JAR) has been described only recently compared to other important signs in dental radiology [1,2,17]. It was first described by Renton et al [2], who conducted a controlled clinical trial and found a significant association between the presence of JAR and the occurrence of nerve injuries

during third molar surgery. In this study, we found JAR to be present in 88 patients (4.4%) out of the 1250 panoramic radiographs and 1960 third molars we evaluated. Out of the 88, 32 (36.4%) were males and 56 (63.6%) were females. There also was an association with teeth that were mesioangularly impacted. Radiographic signs of proximity to the mandibular canal were present in 48 (54.5%) of JAR cases. One (1.13%) of them reported with inferior alveolar nerve injury after the surgical procedure postoperatively.

In 2014, Kapila et al [1] published two research papers on the relation between JAR, the canal, and third molars roots, on DPT and cone-beam computed tomography (CT). JAR was commonly located buccally or superiorly to the canal, and the authors noticed that it was accompanied by a thinning of the cortical plates. They postulated that thinning could be responsible for postoperative paraesthesia after the extraction of third molars, and introduced the concept of disease associated with JAR. Nascimento et al [34] studied 252 patients with a prevalence of 14.7% presenting with JAR. In another paper by Yalcin et al [35], investigated the incidence of juxta-apical radiolucency (JAR) and its relations with surrounding structures using cone-beam computed tomography (CT). o investigate the incidence of juxta-apical radiolucency (JAR) and its relations with surrounding structures using cone-beam computed tomography (CT). Our study supports the idea that JAR is not an independent risk factor for permanent injury to the IAN, and it cannot be the only aspect to guide the treatment plan. We think that further investigations and more literature is needed to elucidate its origins and its role during the removal of third molars. Our institution is passionate about high quality evidence based research and has excelled in various fields ( [22,36–45]. Limitation of this study was that we assessed patients only qualitatively and not quantitatively, as no sensory tests were done. Also, because of the low prevalence of JAR (4.4%) in our population and the low incidence of any injury to the nerve (1.13%), a large number of patients and controls would be needed to generalise the results to the population.

## **Conclusion**

Based on our results, JAR is not an infrequent finding and is more commonly associated with third molars in female patients with the presence of JAR. It is also associated with mesioangular impacted third molars which are partially erupted teeth. These results can be useful in assisting professionals in treatment planning and making the correct diagnosis. Future studies need to be performed to correlate the presence of JAR and its imaging characteristics with a higher incidence of postoperative complication.

## **Acknowledgement**

The authors would like to acknowledge the help and support rendered by the department of oral and maxillofacial surgery and information technology of Saveetha Dental College and Hospitals for their constant assistance with the research

### Conflict of interest

The authors declare no conflicts of interest

### References

1. Kapila R, Harada N, Araki K, Sano T, Goto TK. Evaluation of juxta-apical radiolucency in cone beam CT images. *Dentomaxillofac Radiol* [Internet]. 2014 Apr 2;43(5):20130402. Available from: <http://dx.doi.org/10.1259/dmfr.20130402>
2. Renton T, Hankins M, Sproate C, McGurk M. A randomised controlled clinical trial to compare the incidence of injury to the inferior alveolar nerve as a result of coronectomy and removal of mandibular third molars. *Br J Oral Maxillofac Surg* [Internet]. 2005 Feb;43(1):7–12. Available from: <http://dx.doi.org/10.1016/j.bjoms.2004.09.002>
3. Hatano Y, Kurita K, Kuroiwa Y, Yuasa H, Arijji E. Clinical evaluations of coronectomy (intentional partial odontectomy) for mandibular third molars using dental computed tomography: a case-control study. *J Oral Maxillofac Surg* [Internet]. 2009 Sep;67(9):1806–14. Available from: <http://dx.doi.org/10.1016/j.joms.2009.04.018>
4. Renton T. Prevention of iatrogenic inferior alveolar nerve injuries in relation to dental procedures. *SADJ* [Internet]. 2010 Sep;65(8):342–4, 346–8, 350–1. Available from: <https://www.ncbi.nlm.nih.gov/pubmed/21133047>
5. Salahaldin MGA, Atalay B. Evaluation of the relationship between an impacted mandibular third molar and the inferior alveolar canal using cone-beam computed tomography. *7tepe Klinik* [Internet]. 2018;14(3):99–103. Available from: <https://app.trdizin.gov.tr/publication/paper/detail/TXpFeU1UQXpNdz09>
6. Tantanapornkul W, Okochi K, Bhakdinaronk A, Ohbayashi N, Kurabayashi T. Correlation of darkening of impacted mandibular third molar root on digital panoramic images with cone beam computed tomography findings. *Dentomaxillofac Radiol* [Internet]. 2009 Jan;38(1):11–6. Available from: <http://dx.doi.org/10.1259/dmfr/83819416>
7. Ghaeminia H, Meijer GJ, Soehardi A, Borstlap WA, Mulder J, Bergé SJ. Position of the impacted third molar in relation to the mandibular canal. Diagnostic accuracy of cone beam computed tomography compared with panoramic radiography. *Int J Oral Maxillofac Surg* [Internet]. 2009 Sep 1;38(9):964–71. Available from: <https://www.sciencedirect.com/science/article/pii/S0901502709009473>
8. Neves FS, Souza TC, Almeida SM, Haiter-Neto F, Freitas DQ, Bóscolo FN. Correlation of panoramic radiography and cone beam CT findings in the assessment of the relationship between impacted mandibular third molars and the mandibular canal [Internet]. Vol. 41, *Dentomaxillofacial Radiology*. 2012. p. 553–7. Available from: <http://dx.doi.org/10.1259/dmfr/22263461>
9. Nguyen E, Grubor D, Chandu A. Risk factors for permanent injury of inferior alveolar and lingual nerves during third molar surgery. *J Oral Maxillofac Surg* [Internet]. 2014 Dec;72(12):2394–401. Available from: <http://dx.doi.org/10.1016/j.joms.2014.06.451>
10. Selvi F, Dodson TB, Nattestad A, Robertson K, Tolstunov L. Factors that are associated with injury to the inferior alveolar nerve in high-risk patients after

- removal of third molars. *Br J Oral Maxillofac Surg* [Internet]. 2013 Dec;51(8):868–73. Available from: <http://dx.doi.org/10.1016/j.bjoms.2013.08.007>
11. Susarla SM, Blaeser BF, Magalnick D. Third molar surgery and associated complications [Internet]. Vol. 15, *Oral and Maxillofacial Surgery Clinics of North America*. 2003. p. 177–86. Available from: [http://dx.doi.org/10.1016/s1042-3699\(02\)00102-4](http://dx.doi.org/10.1016/s1042-3699(02)00102-4)
  12. Bouloux GF, Steed MB, Perciaccante VJ. Complications of third molar surgery. *Oral Maxillofac Surg Clin North Am* [Internet]. 2007 Feb;19(1):117–28, vii. Available from: <http://dx.doi.org/10.1016/j.coms.2006.11.013>
  13. Cheung LK, Leung YY, Chow LK, Wong MCM, Chan EKK, Fok YH. Incidence of neurosensory deficits and recovery after lower third molar surgery: a prospective clinical study of 4338 cases [Internet]. Vol. 39, *International Journal of Oral and Maxillofacial Surgery*. 2010. p. 320–6. Available from: <http://dx.doi.org/10.1016/j.ijom.2009.11.010>
  14. Rood JP, Shehab BA. The radiological prediction of inferior alveolar nerve injury during third molar surgery. *Br J Oral Maxillofac Surg* [Internet]. 1990 Feb;28(1):20–5. Available from: [http://dx.doi.org/10.1016/0266-4356\(90\)90005-6](http://dx.doi.org/10.1016/0266-4356(90)90005-6)
  15. Atieh MA. Diagnostic accuracy of panoramic radiography in determining relationship between inferior alveolar nerve and mandibular third molar. *J Oral Maxillofac Surg* [Internet]. 2010 Jan;68(1):74–82. Available from: <http://dx.doi.org/10.1016/j.joms.2009.04.074>
  16. Szalma J, Lempel E, Jeges S, Olasz L. Darkening of third molar roots: panoramic radiographic associations with inferior alveolar nerve exposure. *J Oral Maxillofac Surg* [Internet]. 2011 Jun;69(6):1544–9. Available from: <http://dx.doi.org/10.1016/j.joms.2010.09.009>
  17. Umar G, Bryant C, Obisesan O, Rood JP. Correlation of the radiological predictive factors of inferior alveolar nerve injury with cone beam computed tomography findings. *Oral Surg* [Internet]. 2010 Aug;3(3):72–82. Available from: <http://doi.wiley.com/10.1111/j.1752-248X.2010.01088.x>
  18. Govindaraju L, Gurunathan D. Effectiveness of Chewable Tooth Brush in Children-A Prospective Clinical Study. *J Clin Diagn Res* [Internet]. 2017 Mar;11(3):ZC31–4. Available from: <http://dx.doi.org/10.7860/JCDR/2017/24238.9528>
  19. Christabel A, Anantanarayanan P, Subash P, Soh CL, Ramanathan M, Muthusekhar MR, et al. Comparison of pterygomaxillary dysjunction with tuberosity separation in isolated Le Fort I osteotomies: a prospective, multi-centre, triple-blind, randomized controlled trial. *Int J Oral Maxillofac Surg* [Internet]. 2016 Feb;45(2):180–5. Available from: <http://dx.doi.org/10.1016/j.ijom.2015.07.021>
  20. Soh CL, Narayanan V. Quality of life assessment in patients with dentofacial deformity undergoing orthognathic surgery--a systematic review. *Int J Oral Maxillofac Surg* [Internet]. 2013 Aug;42(8):974–80. Available from: <http://dx.doi.org/10.1016/j.ijom.2013.03.023>
  21. Mehta M, Deeksha, Tewari D, Gupta G, Awasthi R, Singh H, et al. Oligonucleotide therapy: An emerging focus area for drug delivery in chronic inflammatory respiratory diseases. *Chem Biol Interact* [Internet]. 2019 Aug 1;308:206–15. Available from: <http://dx.doi.org/10.1016/j.cbi.2019.05.028>
  22. Ezhilarasan D, Apoorva VS, Ashok Vardhan N. *Syzygium cumini* extract

- induced reactive oxygen species-mediated apoptosis in human oral squamous carcinoma cells. *J Oral Pathol Med* [Internet]. 2019 Feb;48(2):115–21. Available from: <http://dx.doi.org/10.1111/jop.12806>
23. Campeau PM, Kasperaviciute D, Lu JT, Burrage LC, Kim C, Hori M, et al. The genetic basis of DOORS syndrome: an exome-sequencing study. *Lancet Neurol* [Internet]. 2014 Jan;13(1):44–58. Available from: <https://linkinghub.elsevier.com/retrieve/pii/S1474442213702655>
  24. Kumar S, S S. Knowledge and awareness regarding antibiotic prophylaxis for infective endocarditis among undergraduate dental students. *Asian J Pharm Clin Res* [Internet]. 2016 Sep 26;154. Available from: <http://www.innovareacademics.in/journals/index.php/ajpcr/article/view/13405>
  25. Christabel SL. Prevalence of type of Frenal Attachment and morphology of frenum in children, Chennai, Tamil Nadu. *World J Dent* [Internet]. 2015 Dec;6(4):203–7. Available from: <https://www.wjoud.com/doi/10.5005/jp-journals-10015-1343>
  26. Kumar S, Rahman R. Knowledge, awareness, and practices regarding biomedical waste management among undergraduate dental students. *Asian J Pharm Clin Res* [Internet]. 2017 Aug 1;10(8):341. Available from: <https://innovareacademics.in/journals/index.php/ajpcr/article/view/19101>
  27. Sridharan G, Ramani P, Patankar S. Serum metabolomics in oral leukoplakia and oral squamous cell carcinoma. *J Cancer Res Ther* [Internet]. 2017 Jul;13(3):556–61. Available from: [http://dx.doi.org/10.4103/jcrt.JCRT\\_1233\\_16](http://dx.doi.org/10.4103/jcrt.JCRT_1233_16)
  28. Ramesh A, Varghese SS, Doraiswamy JN, Malaiappan S. Herbs as an antioxidant arsenal for periodontal diseases. *J Intercult Ethnopharmacol* [Internet]. 2016 Jan;5(1):92–6. Available from: <http://dx.doi.org/10.5455/jice.20160122065556>
  29. Thamaraiselvan M, Elavarasu S, Thangakumaran S, Gadagi JS, Arthie T. Comparative clinical evaluation of coronally advanced flap with or without platelet rich fibrin membrane in the treatment of isolated gingival recession. *J Indian Soc Periodontol* [Internet]. 2015 Jan;19(1):66–71. Available from: <http://dx.doi.org/10.4103/0972-124X.145790>
  30. Thangaraj SV, Shyamsundar V, Krishnamurthy A, Ramani P, Ganesan K, Muthuswami M, et al. Molecular Portrait of Oral Tongue Squamous Cell Carcinoma Shown by Integrative Meta-Analysis of Expression Profiles with Validations. *PLoS One* [Internet]. 2016 Jun 9;11(6):e0156582. Available from: <http://dx.doi.org/10.1371/journal.pone.0156582>
  31. Ponnulakshmi R, Shyamaladevi B, Vijayalakshmi P, Selvaraj J. In silico and in vivo analysis to identify the antidiabetic activity of beta sitosterol in adipose tissue of high fat diet and sucrose induced type-2 diabetic experimental rats. *Toxicol Mech Methods* [Internet]. 2019 May;29(4):276–90. Available from: <http://dx.doi.org/10.1080/15376516.2018.1545815>
  32. Fluoride, fluoridated toothpaste efficacy and its safety in children - review. *Int J Pharm Res* [Internet]. 2018 Oct 1;10(04). Available from: <http://www.ijpronline.com/ViewArticleDetail.aspx?ID=7041>
  33. Flygare L, Öhman A. Preoperative imaging procedures for lower wisdom teeth removal [Internet]. Vol. 12, *Clinical Oral Investigations*. 2008. p. 291–302. Available from: <http://dx.doi.org/10.1007/s00784-008-0200-1>

34. Nascimento EHL, Oenning ACC, Nadaes MR, Ambrosano GMB, Haiter-Neto F, Freitas DQ. Juxta-apical radiolucency: relation to the mandibular canal and cortical plates based on cone beam CT imaging [Internet]. Vol. 123, Oral Surgery, Oral Medicine, Oral Pathology and Oral Radiology. 2017. p. 401–7. Available from: <http://dx.doi.org/10.1016/j.oooo.2016.12.001>
35. Yalcin ED, Artas A. Juxta-apical radiolucency and relations with surrounding structures on cone-beam computed tomography. *Br J Oral Maxillofac Surg* [Internet]. 2020 Apr;58(3):309–13. Available from: <http://dx.doi.org/10.1016/j.bjoms.2019.12.004>
36. Vijayashree Priyadharsini J. In silico validation of the non-antibiotic drugs acetaminophen and ibuprofen as antibacterial agents against red complex pathogens. *J Periodontol* [Internet]. 2019 Dec;90(12):1441–8. Available from: <http://dx.doi.org/10.1002/JPER.18-0673>
37. Pc J, Marimuthu T, Devadoss P. Prevalence and measurement of anterior loop of the mandibular canal using CBCT: A cross sectional study. *Clin Implant Dent Relat Res* [Internet]. 2018; Available from: <https://europepmc.org/article/med/29624863>
38. Ramesh A, Varghese S, Jayakumar ND, Malaiappan S. Comparative estimation of sulfiredoxin levels between chronic periodontitis and healthy patients - A case-control study. *J Periodontol* [Internet]. 2018 Oct;89(10):1241–8. Available from: <http://doi.wiley.com/10.1002/JPER.17-0445>
39. Ramadurai N, Gurunathan D, Samuel AV, Subramanian E, Rodrigues SJL. Effectiveness of 2% Articaine as an anesthetic agent in children: randomized controlled trial. *Clin Oral Investig* [Internet]. 2019 Sep;23(9):3543–50. Available from: <http://dx.doi.org/10.1007/s00784-018-2775-5>
40. Sridharan G, Ramani P, Patankar S, Vijayaraghavan R. Evaluation of salivary metabolomics in oral leukoplakia and oral squamous cell carcinoma. *J Oral Pathol Med* [Internet]. 2019 Apr;48(4):299–306. Available from: <http://dx.doi.org/10.1111/jop.12835>
41. Mathew MG, Samuel SR, Soni AJ, Roopa KB. Evaluation of adhesion of *Streptococcus mutans*, plaque accumulation on zirconia and stainless steel crowns, and surrounding gingival inflammation in primary molars: Randomized controlled trial. *Clin Oral Investig* [Internet]. 2020;1–6. Available from: <https://link.springer.com/article/10.1007/s00784-020-03204-9>
42. Samuel SR. Can 5-year-olds sensibly self-report the impact of developmental enamel defects on their quality of life? *Int J Paediatr Dent* [Internet]. 2021 Mar;31(2):285–6. Available from: <http://dx.doi.org/10.1111/ipd.12662>
43. R H, Hannah R, Ramani P, Ramanathan A, R JM, Gheena S, et al. CYP2 C9 polymorphism among patients with oral squamous cell carcinoma and its role in altering the metabolism of benzo[a]pyrene [Internet]. Vol. 130, Oral Surgery, Oral Medicine, Oral Pathology and Oral Radiology. 2020. p. 306–12. Available from: <http://dx.doi.org/10.1016/j.oooo.2020.06.021>
44. Chandrasekar R, Chandrasekhar S, Sundari KKS, Ravi P. Development and validation of a formula for objective assessment of cervical vertebral bone age. *Prog Orthod* [Internet]. 2020 Oct 12;21(1):38. Available from: <http://dx.doi.org/10.1186/s40510-020-00338-0>
45. Vijayashree Priyadharsini J, Smiline Girija AS, Paramasivam A. In silico analysis of virulence genes in an emerging dental pathogen *A. baumannii* and

related species. Arch Oral Biol [Internet]. 2018 Oct;94:93–8. Available from: <http://dx.doi.org/10.1016/j.archoralbio.2018.07.001>